

9. Figure 5-3, A-C shows lateral, anterior, and inferior views of the skull. Select different colors for the bones listed below and color the coding circles and corresponding bones in the figure. Complete the figure by labeling the bone markings indicated by leader lines.

- | | | | |
|--------------------------------|--------------------------------|---------------------------------|--------------------------------|
| <input type="radio"/> Frontal | <input type="radio"/> Sphenoid | <input type="radio"/> Zygomatic | <input type="radio"/> Nasal |
| <input type="radio"/> Parietal | <input type="radio"/> Ethmoid | <input type="radio"/> Palatine | <input type="radio"/> Lacrimal |
| <input type="radio"/> Mandible | <input type="radio"/> Temporal | <input type="radio"/> Occipital | <input type="radio"/> Vomer |
| <input type="radio"/> Maxilla | | | |

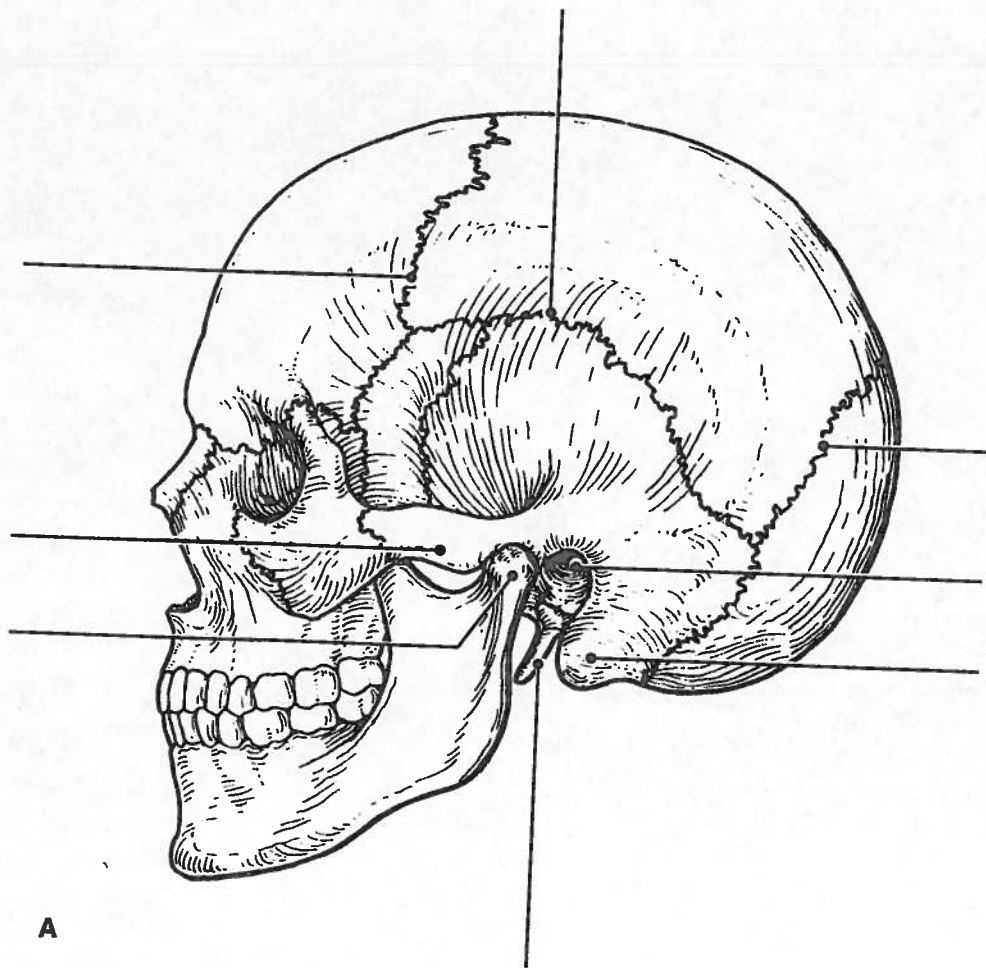
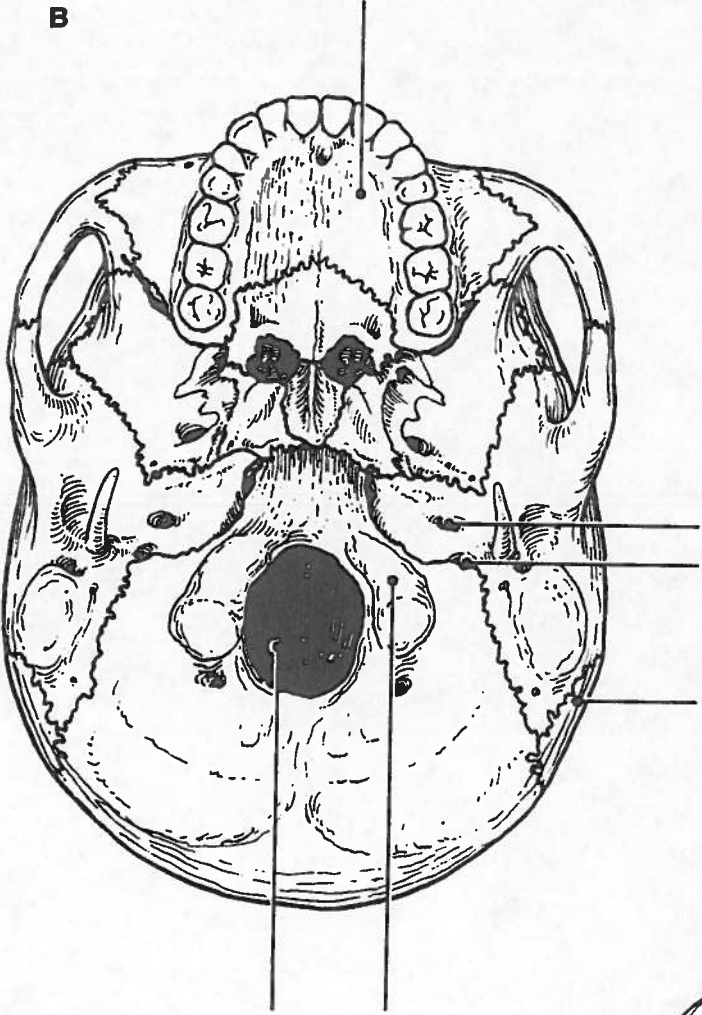
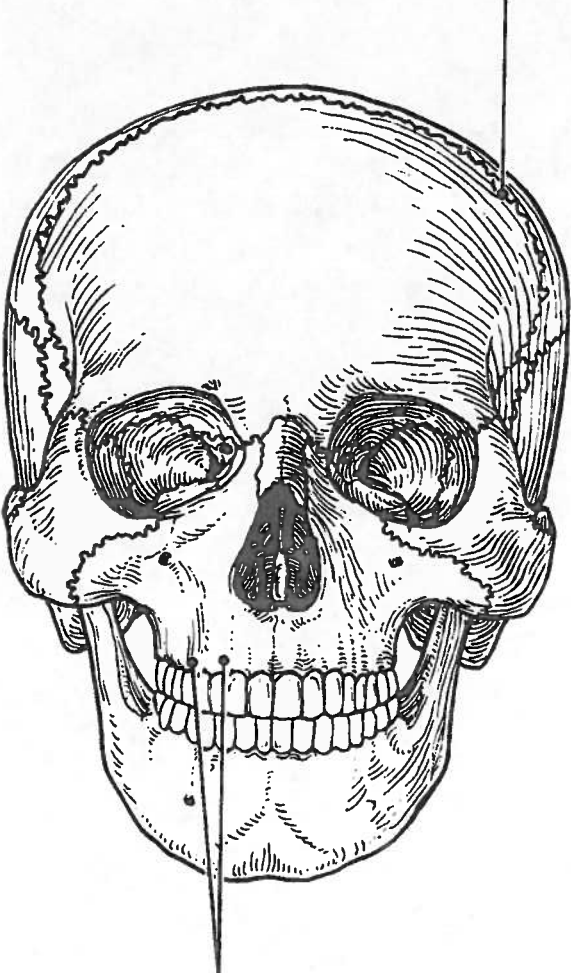


Figure 5-3, A-C

B



C



15. Figure 5-6 is a lateral view of the vertebral column. Identify each numbered region of the column by listing in the numbered answer blanks the region name first and then the specific vertebrae involved (for example, sacral region, S# to S#). Also identify the modified vertebrae indicated by numbers 6 and 7 in Figure 5-6. Select different colors for each vertebral region and use them to color the coding circles and the corresponding regions.

- 1. _____ ○
- 2. _____ ○
- 3. _____ ○
- 4. _____ ○
- 5. _____ ○
- 6. _____ ○
- 7. _____ ○

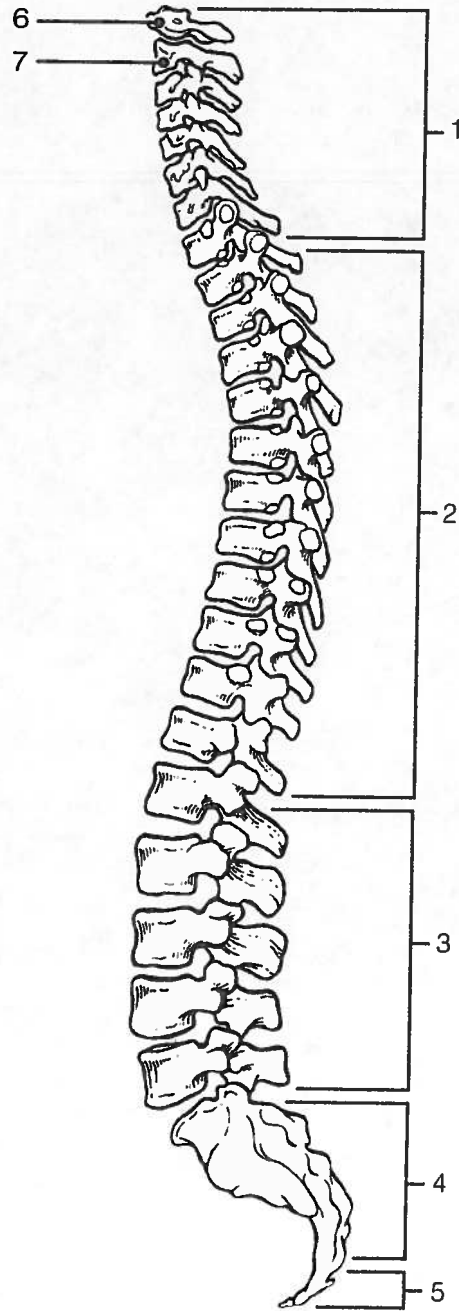


Figure 5-6

Bony Thorax

16. Complete the following statements referring to the bony thorax by inserting your responses in the answer blanks.

- _____ 1. The organs protected by the thoracic cage include the (1) _____ and the (2) _____. Ribs 1 through 7 are called (3) _____ ribs, whereas ribs 8 through 12 are called (4) _____ ribs. Ribs 11 and 12 are also called (5) _____ ribs. All ribs articulate posteriorly with the (6) _____, and most connect anteriorly to the (7) _____, either directly or indirectly.
- _____ 2.
- _____ 3.
- _____ 4.
- _____ 5. The general shape of the thoracic cage is (8) _____.
- _____ 6.
- _____ 7.
- _____ 8.

17. Figure 5-7 is an anterior view of the bony thorax. Select different colors to identify the structures below and color the coding circles and corresponding structures. Then label the subdivisions of the sternum indicated by leader lines.

- All true ribs All false ribs
- Costal cartilages Sternum

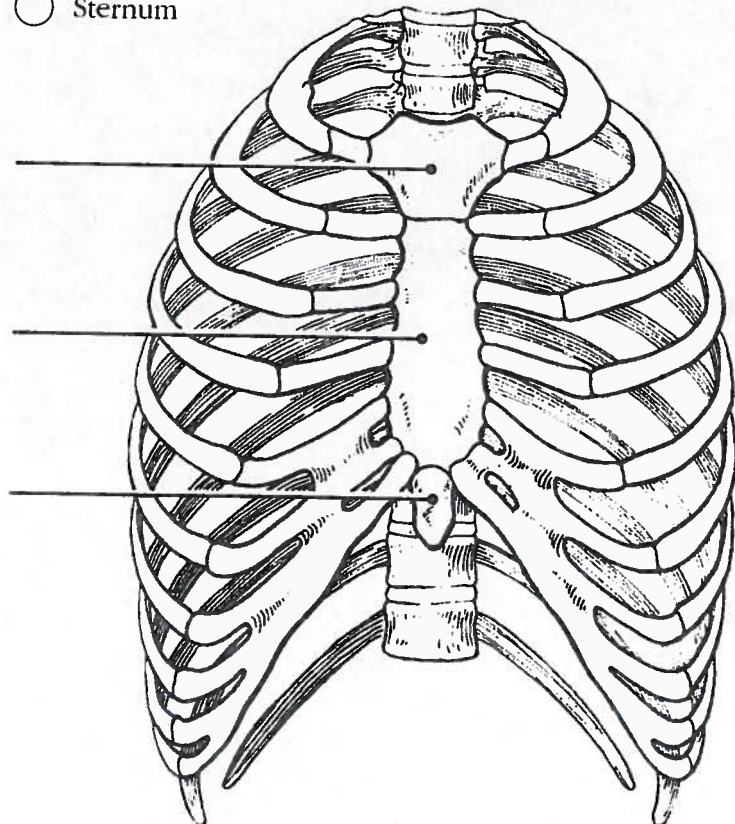


Figure 5-7